

Hypospadias surgery: when, what and by whom?

GIANANTONIO MANZONI, AIVAR BRACKA*, ENZO PALMINTERI† and GIACINTO MARROCCO‡

Department of Urology and Section of Paediatric Urology, Ospedale di Circolo, Varese, Italy, *Department of Plastic Surgery, Wordsley Hospital, Stourbridge, West Midlands, UK, †Centre for Urethral and Genitalia Reconstructive Surgery, Arezzo, and ‡Department of Paediatric Surgery, Ospedale S. Camillo, Rome, Italy

SUMMARY

Hypospadias is repaired by paediatric surgeons, paediatric urologists, adult reconstructive urologists and plastic surgeons. This review is unique in representing all four specialities, to provide a unified policy on the management of hypospadias. The surgeon of whichever speciality should have a dedicated interest in this challenging work, ideally having an annual volume of at least 40–50 cases. The ideal time for primary repair is at 6–12 months old, although when this is not practicable there is another opportunity at 3–4 years old. A surgical protocol is presented which emphasises both functional and cosmetic refinement. Using a logical progression of a very few related procedures allows the reliable correction of almost any hypospadias deformity. A one-stage repair is used when the urethral plate does not require transection and its axial integrity can be maintained. Occasionally, when the plate is of adequate width and depth, it can be tubularized directly using the second stage of the two-stage repair. When (usually) the urethral plate is not adequately developed and requires augmentation before it can be tubularized, then that second-stage procedure is modified by adding a dorsal releasing incision ± a graft (alias Snodgrass and 'Snodgraft' procedures). The two-stage repair offers the most reliable and refined solution for those patients who require transection of the urethral plate and a full circumferential substitution urethroplasty. From available evidence this protocol combines excellent function and cosmesis with optimum reliability. Nevertheless, it would be complacent to assume that these gratifying results will be maintained into adult life. We therefore recommend that there is still a need for active follow-up through to genital maturity.

INTRODUCTION

Hypospadias is one of the most common malformations of male genitalia, with a

traditionally quoted incidence of 1 in 300 male births. However, epidemiological evidence suggests that in developed Western countries the incidence is increasing [1], and may be as high as 8 in 1000 male births. Both genetic and environmental factors are implicated in the cause and numerous theories have been proposed about both the cause and the changing prevalence [2–4], but discussion of these falls outside the remit of this review.

There is no single satisfactory way of classifying hypospadias. Despite obvious limitations, preoperative meatal position remains the most commonly used criterion. By this classification at least 70% of hypospadias is either glanular or distal penile, 10% mid-penile, and 20% the more severe proximal types.

Table 1 and Fig. 1 summarize the principal anatomical variables associated with the spectrum of hypospadias severity, and list the expected findings. Unfortunately hypospadias deformities do not necessarily conform to these expectations, so this is only a broad generalization. The position of the meatus alone is therefore not a reliable indicator of hypospadias severity as far as the choice of an appropriate surgical correction is concerned. Occasionally, a distal hypospadias may have severe curvature with a poorly developed urethral plate and glans groove, whilst a proximal hypospadias may have the opposite features.

Our proposed surgical protocol is determined more by these other anatomical variables, in particular the quality of the urethral plate, the glans configuration, and degree and type of curvature. This has allowed the confusing and vast array of available repairs to be narrowed to a simple and logical progression of just a few related procedures.

PREOPERATIVE EVALUATION

Hypospadias is generally an isolated anomaly but it may represent one of the features of

over 200 different syndromes [5]. Associated malformations of the urinary tract are most common in proximal or complex hypospadias, but their incidence in distal forms is no different from that of the general population. The most frequently encountered anomalies are

- Inguinal hernia.
- Undescended testis.
- PUJ obstruction.
- Renal agenesis.
- VUR.
- Persistent Müllerian structures.
- Intersex states.

It is therefore unnecessary to undertake formal investigation of the urinary tract for simple distal hypospadias, unless associated with unexplained symptoms. However, proximal hypospadias requires a more thorough evaluation. If one or both testes are impalpable, it may signify the presence of an intersex condition such as adrenogenital syndrome or a mixed gonadal dysgenesis. In this instance there should always be a karyotype study and ultrasonography of the urinary tract and internal genital organs [6].

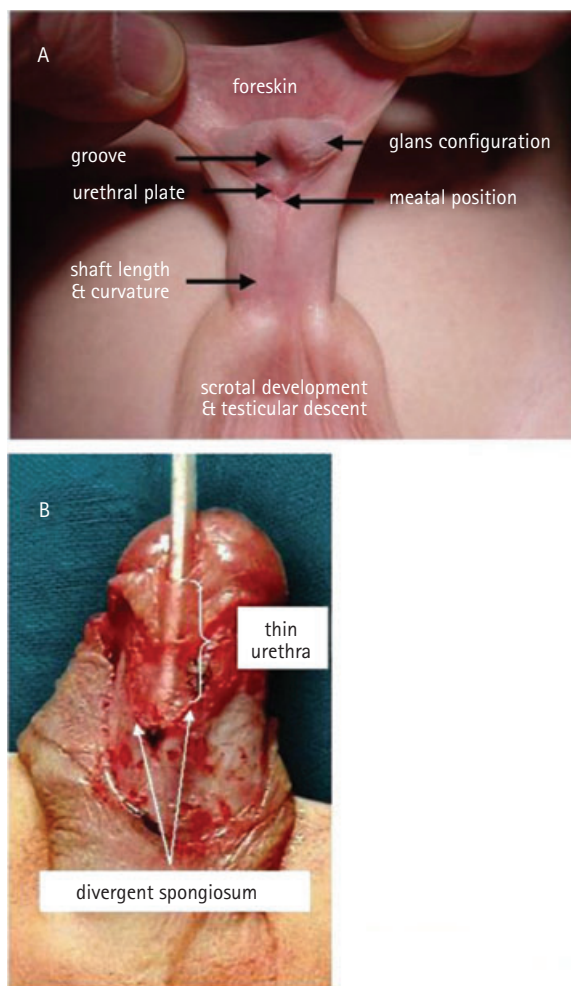
Furthermore, endoscopic examination of the urethra at the time of surgery is necessary to exclude the presence of a Müllerian remnant (dilated utriculus). Accurate assessment of the type of hypospadias, for severity of curvature and the urethral quality, is often possible only with the patient under anaesthesia, and this may therefore lead to modification of the surgical plan.

THE TIMING OF SURGICAL REPAIR

Whenever possible it is helpful to assess the problem during the first few weeks of life. This reduces the parental guilt and 'fear of the unknown' that is typically associated with congenital birth defects, whilst at the same time establishing a bond between the parents and the surgeon that is instrumental to future management.

Anatomy	Condition	TABLE 1 <i>Anatomical variables in hypospadias</i>
Foreskin	well/poorly developed/absent	
Glans and groove configuration	shallow + conical deep + well developed	
Urethral plate	well developed/hypoplastic broad/narrow	
Penile size	normal/reduced	
Curvature	present/absent	
Meatal position		
Scrotum	normal/hypoplastic bifid/transposed	

FIG. 1.
(A,B), anatomical variables in the
hypospadias complex.



Factors that can influence the timing of hypospadias repair include the environment in which the patient will be managed, anaesthetic risk, penile dimensions and the psychological effect of genital surgery. After the age of 6 months the risk of anaesthesia is no greater than when older [7], provided the anaesthesia is administered by a specialist

paediatric anaesthetist and the patient cared for in a designated paediatric facility.

Penile size is not a limiting factor in most children and as only moderate penile growth occurs in the first few years of development, there is no technical advantage in delaying surgery. At 1 year old penile length is, on

average, only 0.8 cm less than at pre-school age [8]. With a very small phallus, use of hormonal stimulation to achieve penile enlargement is now less controversial, because initial concerns about subsequent down-regulation of androgen receptors appear to be unfounded. Testosterone enanthate (25 mg) administered intramuscularly 1 month before surgery or topical dihydrotestosterone cream, applied daily for 1 month, are both viable options [9].

Genital awareness does not begin until 18 months of age; this also heralds the start of a difficult and uncooperative behavioural phase in the child's development, which makes him ill-suited to hospitalization. It is not until 3 years old that the child becomes sufficiently mature to collaborate with his treatment, and this then presents a second opportunity for primary hypospadias repair. This pre-school period, age 3–4 years, is a more workable option for those surgeons who do not practise in a specialized paediatric facility, and seems to produce similar outcomes to those of surgery undertaken during the first year of life.

Recommendations from the Section of Urology of the American Academy of Pediatrics now suggest that the optimum time for elective surgery on the genitalia is either in the second 6 months of life or sometime during the fourth year [10,11]. We therefore conclude that where practical, the ideal time to correct primary hypospadias is when aged 6–12 months.

SURGICAL TREATMENT

The modern surgical repair of hypospadias requires an experienced dedicated specialist, whether a paediatric urologist/surgeon, a plastic surgeon (or an adult reconstructive urologist). This is not surgery for the occasional operator, therefore a volume of at least 40–50 cases per year is desirable.

With advances in surgical techniques and suture materials, use of optical magnification and microsurgical instrumentation, hypospadias repair has developed into a safe and reliable procedure, with a very high reported success rate. Dedicated paediatric facilities and paediatric anaesthetic support are essential to the success of short-stay surgery in very young children. A further requirement

is the routine use of intraoperative caudal or penile local anaesthetic blocks as part of an effective postoperative analgesic regimen.

In first-world countries the trend is towards earlier intervention with ever-shorter hospitalization; indeed, in many centres the norm is now for a single-stage repair undertaken as a day-case during the first year of life. The purpose of this is not merely to reduce costs, but also has the potential benefit of reducing the psychological impact of surgery and the separation anxiety that may be associated with hospitalization.

Early day-case repair may be a safe, realistic and desirable prospect when sophisticated surgery and anaesthesia can be combined with high standards of community aftercare. However, in many parts of the world, even in developed countries, this ideal cannot be achieved for various reasons, and therefore pre-school surgery and longer periods of hospitalization may still be preferred.

Patient co-operation is not a requisite in very young infants, and an open system with a dripping stent and double-diaper method of dressing will adequately contain the urine drainage and prevent the child from interfering with the operation site. A wide-lumen indwelling silicone Foley catheter is preferred in the older patient, ranging from 8 F in a child through to 12 F in an adult; currently, suprapubic diversion is seldom justified.

The choice of dressings, use of prophylactic antibiotics and decisions about urinary diversion are not universally agreed. These remain areas of individual surgeon preference, influenced by the severity of the hypospadias and the type of repair used.

SELECTING THE SURGICAL PROCEDURE

The goal of primary hypospadias repair is to achieve both cosmetic and functional normality. Whether this is by a single procedure or with a staged approach, it requires the creation of a straight penis, with an even calibre of neourethra, terminating in a natural slit-like meatus at the apex of a naturally reconfigured glans.

Ironically, the very distal forms, which account for the vast majority of hypospadias, are sometimes the most challenging in terms



FIG. 2.

The final outcome of the Snodgrass repair.

of the decision-making process, because cosmesis is often the only real indication for treatment. Foreskin preservation and reconstruction may be an issue because of local cultural pressures or parental preference, and when the penile skin configuration allows for this, then the prepuce can be successfully reconstructed [12–14]. However, there are still as yet no published long-term data on the sexual function of these reconstructed foreskins.

At the other end of the spectrum, perineal hypospadias represents the most challenging and technically demanding surgical exercise, involving both urethral reconstruction and correction of penile curvature, and variable degrees of penoscrotal transposition.

No attempt should be made to understate the complexity of hypospadias repair, and the benefits of correction should always outweigh the potential risks. The choice of technique is determined by the anatomical characteristics previously described (Fig. 1). Despite the very many reconstructive techniques now available, the authors feel that a simple and reliable protocol can be applied, mostly based on the quality and development of the urethral plate, rather than the preoperative location of the meatus. The one-stage repair comprises urethral plate tubularization (using a glanular approximation or Snodgrass procedures) and urethral plate augmentation (onlay flap, Snod-graft). The two-stage repair uses urethral plate substitution (Bracka).

URETHRAL PLATE TUBULARIZATION

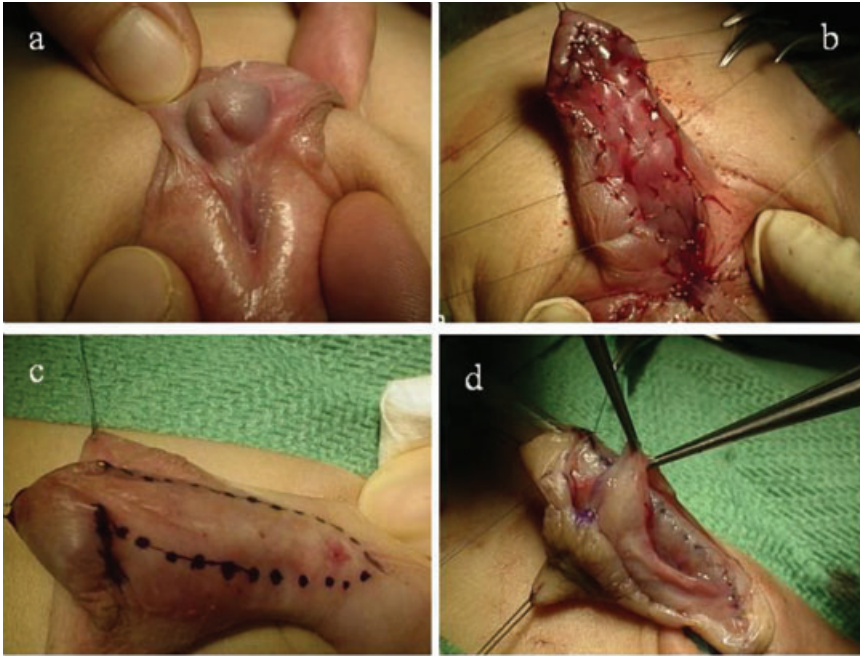
When the urethral plate does not require transection and its axial integrity can be

maintained, it is possible to tubularize it. Occasionally, when the plate is of adequate width and depth, it can be tubularized directly, as described by Zaon [15] (glanular approximation procedure). Conversely, when the plate is not adequately developed and requires more width/depth before it can be tubularized, a midline deep dorsal releasing incision can be added, according to the Snodgrass procedure [16]. This tubularized incised-plate (TIP) repair was first described in 1994, and has gained worldwide popularity as a solution for distal primary hypospadias, but it has subsequently also gained acceptance for suitable proximal forms of hypospadias and, more recently, for selective use in re-operations [17]. Initial concerns about the potential for stricture development have not been substantiated, at least in the short term, and the Snodgrass repair is currently providing better cosmetic and functional results than other techniques (Fig. 2).

URETHRAL PLATE AUGMENTATION

Despite the potential enhancement of width with the midline releasing incision, there are occasionally narrow and inelastic urethral plates that require more substantial augmentation. This can apply to distal hypospadias, but more particularly to severe penile forms where the application of an extended Snodgrass procedure may generate concerns for the long-term outcome. The onlay preputial island flap, as popularized by Duckett [18], can be used in the vast majority of these cases, and for many surgeons still represents an ideal solution. However, a more recently developed and increasingly popular concept is the 'Snod-graft' repair. This represents a logical progression of the original Snodgrass principle, wherein a free

FIG. 3. Primary Bracka two-stage repair for proximal hypospadias: A,B, first stage with inner preputial layer free graft; C,D, second stage after 6 months.



graft is quilted into the dorsal defect rather than leaving it to epithelialize. This is a useful procedure when the glans configuration is more conical, with a minimal groove and lacking the usual external rotation of the glans wings. To achieve an apical meatus would in this instance necessitate extension of the Snodgrass dorsal-releasing incision beyond the distal limit of the glans groove, and thereby invite a meatal stricture, unless the defect is grafted. The 'Snod-graft' concept is particularly useful in repeat salvage cases and is further discussed in the section on hypospadias failures.

URETHRAL PLATE SUBSTITUTION

In the presence of severe proximal forms, with significant ventral chordee, urethral plate transection becomes inevitable, and a full circumferential substitution urethroplasty is then required. Single-stage tubularized repairs, the most popular being the Duckett TPIF [19], have been largely abandoned because of their prohibitive long-term complication rate. A two-stage procedure such as described by Bracka [20] is regarded by many as a better option. For primary cases the inner preputial skin layer is used as a free full-thickness (Wolfe) graft (Fig. 3). If the prepuce is poorly developed or absent because of circumcision, then buccal mucosa

or nongenital skin can be used, either in addition to prepuce or as an alternative to it. This allows for optimum release of ventral chordee tissue and preservation of penile length. However, remaining inherent corporeal disproportion may still require correction by a dorsal Nesbit procedure. When this would lead to unacceptable shortening of an already hypoplastic organ, consideration may be given to ventral tunica release and lengthening with dermal or tunica vaginalis grafts [21,22]. In the absence of any published long-term data some caution is required, because erectile dysfunction is a well recognized complication in adults who undergo tunica-grafting procedures for curvature correction.

FOLLOW-UP PROTOCOL

Traditional thinking has been that any significant complications will have presented within the first 2 years after surgery and therefore follow-up beyond this time is not a cost-effective use of scarce resources. It is assumed that patients will seek review for the few problems that may arise later. Early discharge has also been justified on the grounds that it is best to let the patient forget that he had a genital abnormality, as repeatedly bringing the fact to his attention might actually generate psychological

concerns. Evidence from adult studies, cited below, clearly refute these assumptions and show that early discharge is just a convenient way to 'sweep problems under the carpet' and allow for flattering 're-operation rates' which bear little relation to the true complication rate.

An ideal protocol should include an early evaluation within 3 months of surgery, followed by a review at 1 or 2 years, and again at 4 or 5 years. The quality of micturition should be assessed subjectively, and when possible confirmed objectively with uroflowmetry and perhaps bladder ultrasonography before and after voiding. With the onset of rapid growth at puberty there is the potential for new problems to arise; a previously unrecognized and asymptomatic microfistula might start to leak; a scarred neourethra may fail to grow adequately; or the shape of the penis may cause concern. The patient should therefore be reassessed at puberty and again at around the mid-teens, by which time genital maturation will be at or near completion and the patient able to comment about social and sexual aspects of the penile surgery.

HYPOSPADIAS FAILURES: MORE OFTEN THAN WE THINK?

Using the above protocols to repair primary hypospadias, early 're-operation' rates of <10% are a realistic goal. However, disconcerting evidence from adult review studies [23] suggests that the true long-term complication or dissatisfaction rates may be significantly higher.

The landmark study by Mureau *et al.* [24] found that almost half of the adolescents they reviewed were prepared to consider further surgery if their penises could be made to look more normal. Interestingly, they found that there was no statistical difference in subsequent social and sexual adjustment between those having single-stage repairs in the first year of life and those having two-stage surgery at around school age. In other words, what really determines patient satisfaction is the quality of functional and cosmetic outcome rather than the means by which it is achieved.

Unfortunately, despite the compelling evidence, few hypospadias centres

actively follow their patients. Instead, the responsibility is placed with the family to request a review appointment if and when problems arise, or when the boy reaches maturity. The large adult review study by Bracka [25] shows this to be a naive policy. About half the patients in that study took the opportunity to have their hypospadias repairs surgically revised, even though they had originally been discharged in childhood with an apparently satisfactory outcome. Had it not been for the request to return for review, few of these young adults would have sought help by their own initiative, either because of embarrassment, resignation or ignorance that further improvement was possible.

It is probable that the currently more sophisticated repairs will not reproduce quite the same alarming rates of late dissatisfaction. One of the authors (A.B.) has now followed several hundred patients with two-stage repairs through to genital maturity, and is heartened to encounter very few late concerns with either function or cosmesis. Urethrae created from free preputial grafts grow just as well as those created from flaps, but we still know relatively little about the long-term behaviour and growth of less androgen-sensitive tissues such as buccal mucosa. There is as yet no long-term data on the Snodgrass repair, and there are still other unresolved issues to document, such as the late outcome of childhood Nesbit procedures or of foreskin reconstruction. Until this information becomes available we should maintain an active long-term follow-up policy, both for our education and for the patients' welfare.

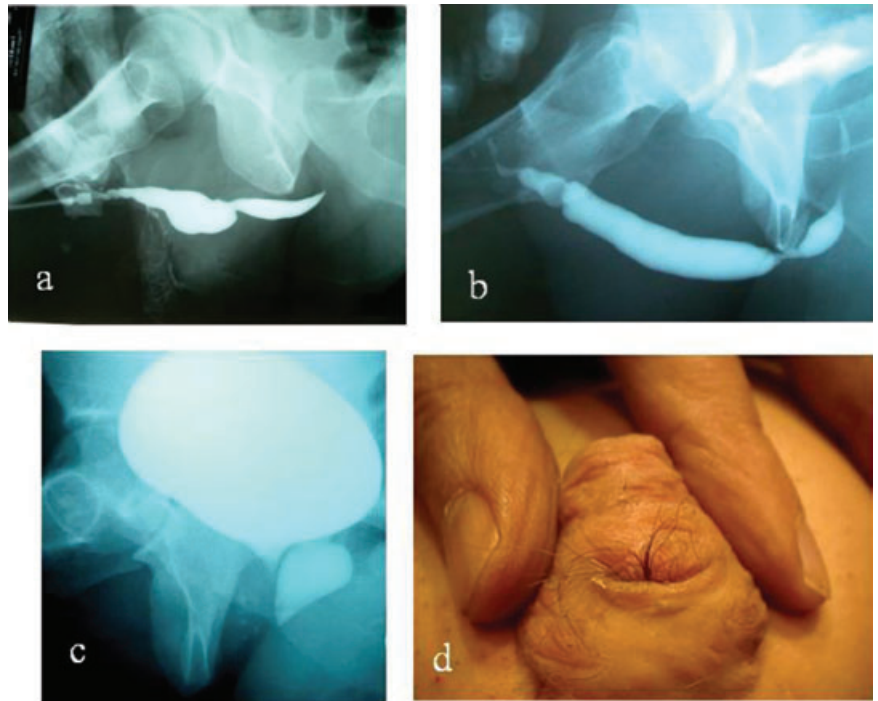
COMPLICATIONS: EARLY AND LATE

Patient dissatisfaction may be wide ranging:

Urinary dysfunction; (a) obstructive-irritating symptoms with or with no recurring infections caused by strictures, diverticulae, urethral stones and hairs; (b) misdirection or spraying of the urinary stream caused by ectopic or misshapen meatus, stricture or fistula; (c) false incontinence (postvoid dribbling) caused by megalo-urethra or diverticulum.

Sexual dysfunction; (a) difficult penetration caused by residual chordee, restricting or deforming scars, penile hypoplasia; (b) poor ejaculation caused by urethral stricture, dilatation or diverticulum.

FIG. 4. Retrograde and voiding cysto-urethrogram: A, stricture and diverticulum of the neourethra; B, an unrecognized and unrelated proximal stricture; C, enlarged prostatic utricle; D, a hairy urethra.



Appearance: (a) abnormal glans and meatus configuration, prominent scarring and skin asymmetry, are inherent to many types of repair; (b) absence of foreskin may cause self-awareness in some communities; (c) short penis, bifid or abnormally inserted scrotum; these are often associated with proximal hypospadias.

In older patients, the perception of an abnormal penis can lead to 'locker-room syndrome' and reluctance to pursue sexual relationships. Further to correcting any residual hypospadias deformities, body-image counselling and sympathetic consideration for penis-lengthening procedures may also be appropriate.

INVESTIGATIONS

Sometimes, taking an adequate history and examination may be sufficient to determine the problem and to recommend appropriate management. For instance, a long unexplained history of recurring or late-onset strictures should immediately raise the suspicion of balanitis xerotica obliterans (BXO, lichen sclerosus). The clinical findings of an indurated neourethra with typical white discoloration and fibrosis around the meatus

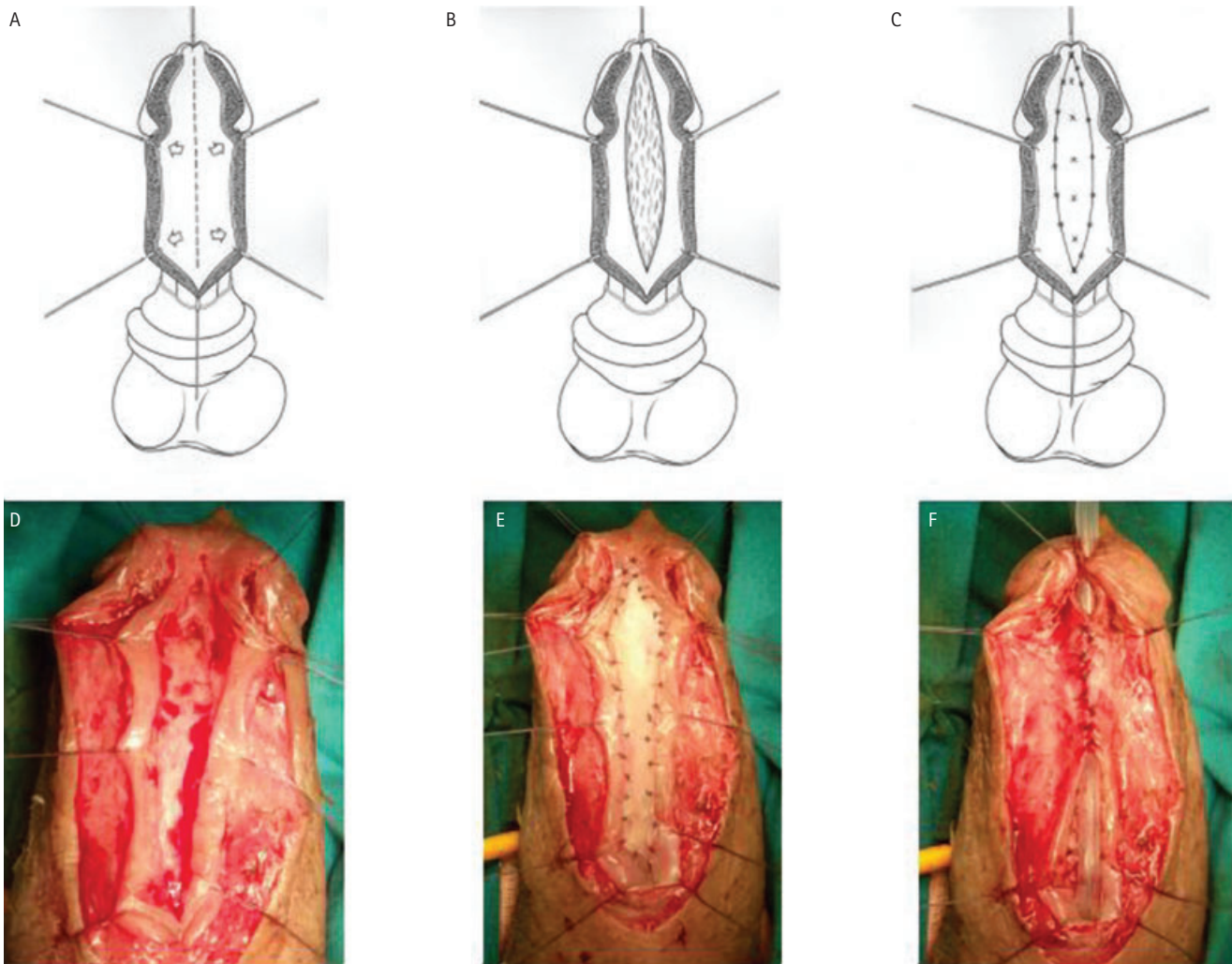
make the diagnosis almost beyond doubt, but for absolute certainty it can then be confirmed by histological biopsy.

Preoperative urine analysis and uroflowmetry, together with detailed investigation of the lower urinary tract using retrograde and voiding cysto-urethrography and urethroscopy, provide important information about urinary dysfunction. This information is valuable not only for determining appropriate treatment, but also as a tool to help explain and justify the proposed management to the patient. These investigations may determine the presence, severity and extent of abnormalities of the neourethra, e.g. stricture, diverticulum, hairs, stones and dysplasia/neoplasia. They may also bring to light an unrecognized and unrelated proximal stricture, or a prostatic utricle, both of which may cause unexpected difficulties with catheterization (Fig. 4)

MANAGEMENT

One of the authors (A.B.) has treated hundreds of disgruntled teenagers and adults with failed hypospadias repairs, many of whom have been in and out of hospital ever since early childhood, and have lost all faith in the

FIG. 5. A 'Snod-graft' repair with buccal mucosal free graft; A–C, diagrammatic outline; D, midline dorsal incision of the urethral plate; E, a free graft quilted into the dorsal defect; F, initial tubularization of the augmented neourethra.



medical profession. Spending quality time addressing their socio-sexual concerns and aspirations, in addition to providing adequate clinical information about the salvage surgical options, is an essential part of the trust-building and rehabilitation process. Some surgeons may delegate part of this process to a sympathetic body-image counsellor or clinical psychologist.

The principles of salvage surgery are not dissimilar to those already described for primary repair, but faced with already scarred, less vascular and perhaps deficient tissues, this surgery is often a greater technical challenge and not surprisingly carries a somewhat higher complication rate. Postoperative erections can be distressing or disruptive in the older patient, and this

trauma can be reduced by using perioperative antiandrogen therapy or topical cold sprays [20].

ONE-STAGE REPEAT SURGERY

As with primary hypospadias repair, when the axial integrity of the neourethra can be maintained for at least part of its circumference (e.g. fistula repair, urethral reduction or augmentation stricture-plasty), then repair can be safely effected in a single operation.

Simple fistula repair is usually successful provided that there is no associated problem with the calibre of the urethra, and that attention is paid to separating suture lines. This can be achieved either by interposing a

dartos fascia 'waterproofing' flap between the urethra and skin, or using advancement or rotation of skin flaps to offset the skin closure.

Whilst the Snodgrass TIP repair has revolutionized the primary correction of hypospadias, it is less well suited to repeat urethral augmentation. First, the surgeon is likely to be incising into previously operated, less vascular tissues that will therefore have a greater propensity to heal by contraction and scarring. Furthermore, whilst the size of the dorsal wall defect may be proportionately the same as for primary repair, in absolute terms the size of defect that is required to re-epithelialize will be much larger in an adult penis. The problem is overcome by quilting a free

graft of buccal mucosa (or inner preputial skin if still available) into the dorsal defect [26–29], thereby creating a graft-augmented Snodgrass or 'Snod-graft' repair (Fig. 5).

Free augmentation grafts in the adult penile urethra should be placed as dorsal inlays rather than ventral onlays, because the ventral soft tissues of a hypospadiac penis provide poor vascular and mechanical support for a free graft. Ventral onlay would therefore result in a greater likelihood of graft failure, fistula formation or urethral dilatation.

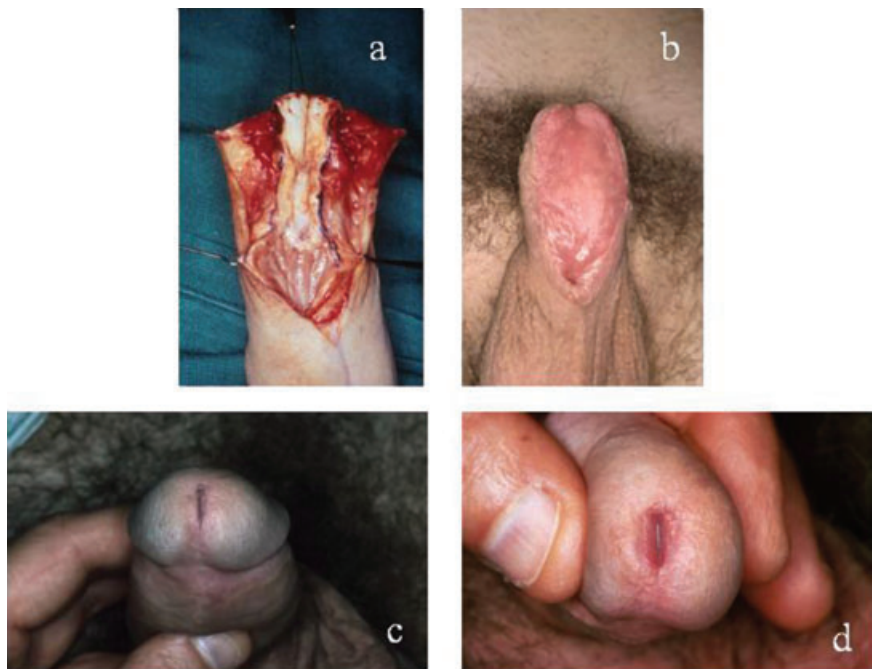
TWO-STAGE REPEAT SURGERY

When a full circumferential substitution urethroplasty is required (e.g. when ventral chordee release with urethral lengthening is preferred to a dorsal Nesbit procedure, or when replacing a hairy or BXO-diseased urethra), then a two-stage procedure such as described by Bracka [20] is the best option (Fig. 6).

The advent of buccal mucosa as a urethral substitution material has revolutionized the management of these challenging cases. Unlike bladder mucosa, which is an obligatory wet mucosa that therefore has to be used as a one-stage tube and kept away from the meatus, buccal mucosa is a robust material that can be left exposed to the air for long periods. For this reason it can be used for two-stage urethroplasty in much the same way as a full-thickness skin graft. By allowing 4–6 months between the operations, the graft has adequate opportunity to mature and complete any contraction that may take place.

With this in mind usually a slightly wider than required graft is placed at the first stage. Any surplus width can always be discarded, along with the lateral junctional scars at the second stage. Conversely, should there be a significant area of narrowing, there is then the opportunity to augment this site with a dorsal inlay patch graft at the time of the second stage. Because the graft width, the meatal margins and the proximal junctional area are already matured at the time of tubularization, no maintenance in the form of self-dilatation will be necessary after surgery. This is in contradistinction to single-stage buccal graft tubes, which have complication rates of up to half and require a prolonged period of calibration after repair to prevent the formation of junctional strictures.

FIG. 6. The Bracka two-stage repeat repair for BXO/urethral stricture in hypospadias failure. A, the urethral stricture clearly visible; B, buccal mucosal free graft after 6 months, ready for second-stage closure; C, the final outcome with glanular reconstruction completed; D, a closer view of the meatal appearance.



In most instances sufficient mucosa can be harvested from the mouth to replace the entire penile urethra without creating secondary donor-site morbidity. Whilst the lower lip is a useful source of mucosa for augmentation patch grafting, the cheeks are the preferred donor site for full-width substitution urethroplasty. This is particularly so in adults, wherein the mouth to penis size ratio is considerably less favourable than in children. Cheek donor sites should be closed directly to minimize postoperative discomfort. Taking into account the bacterial flora of the oral cavity, antibiotic prophylaxis should cover anaerobic organisms as well as usual urinary pathogens, hence our preference for coamoxiclav.

BXO is one of the most important yet often unrecognized causes of late hypospadias failures. One author (A.B.) has treated more than 100 cases of hypospadias complicated by the presence of histologically confirmed BXO [30]. When BXO is still confined to the penile urethra the only effective long-term solution is to substitute the entire diseased segment with buccal mucosa. In the case of neglected disease that has been allowed to spread proximally to involve the bulbar urethra, a combination of buccal and bladder mucosa will then be required.

Augmentation procedures, dilatations and endoscopic urethrotomies do not cure BXO. They provide only temporary relief, whilst allowing insidious progression of disease down the urethra. Substitution with genital skin leads to re-stricture usually within a couple of years. Nongenital skin, such as postauricular Wolfe grafts, may remain healthy for much longer, and an early discharge policy can therefore induce false optimism. However, almost every reconstruction with nongenital skin will also have re-strictured within 10 years.

CONCLUSIONS

We present a simple and reliable protocol for correcting almost all primary and repeat hypospadias, using only a very few logically related surgical procedures. In essence, this protocol depends on the quality and development of the urethral plate, rather than the preoperative location of the meatus.

REFERENCES

- 1 Paoluzzi LJ. Is hypospadias an 'environmental' birth defect?. *Dialogues Pediatric Urol* 2000; **23**: 2–4
- 2 Landrigan P, Garg A, Droller DB.

- Assessing the effects of endocrine disruptors in the National Children's Study. *Environ Health Perspect* 2003; **111**: 1678–82
- 3 Aaronson IA, Murat AC, Key LL. Defect of the testosterone biosynthetic pathway in boys with hypospadias. *J Urol* 1997; **157**: 1884–8
 - 4 Baskin LS. Anatomical studies of the fetal genitalia: surgical reconstructive implications. *Adv Exp Med Biol* 2002; **511**: 239–49
 - 5 Moreno-Garcia M, Miranda EB. Chromosomal anomalies in cryptorchidism and hypospadias. *J Urol* 2002; **168**: 2170–2
 - 6 Kaefer M, Diamond D, Hendren WH *et al*. The incidence of intersexuality in children with cryptorchidism and hypospadias: stratification based on gonadal palpability and meatal position. *J Urol* 1999; **162**: 1003–6
 - 7 Betts EK. Anesthesia in the neonate and young infant. *Dialogues Pediatric Urol* 1981; **4**: 3
 - 8 Schonfeld WA, Beebe GW. Normal growth and variation in the male genitalia from birth to maturity. *J Urol* 1942; **48**: 759–61
 - 9 Tsur H, Shafir R, Shachar J. Microphallic hypospadias: testosterone therapy prior to surgical repair. *Br J Plast Surg* 1983; **36**: 398–400
 - 10 Kelalis P, Bunge R, Barkin M *et al*. The timing of elective surgery on the genitalia of male children with particular reference to undescended testes and hypospadias. *Pediatrics* 1975; **56**: 479–83
 - 11 Lepore AG, Kesler RW. Behaviour of children undergoing hypospadias repair. *J Urol* 1979; **122**: 68–71
 - 12 Podesta E, Buffa P, Di Rovasenda E, Scarsi P. La ricostruzione del prepuzio nelle ipospadie distali. Proposta di una modifica alla tecnica di Righini. *Rass It Chir Ped* 1985; **27**: 273–6
 - 13 Frey P, Cohen SJ. Reconstruction of foreskin in distal hypospadias repair. *Progr Pediatr Surg* 1989; **23**: 192–4
 - 14 Erdenetsetseg G, Dewan PA. Reconstruction of the hypospadiac hooded prepuce. *J Urol* 2003; **169**: 1822–4
 - 15 Zaontz MR. The GAP (glans approximation procedure) for glanular/coronal hypospadias. *J Urol* 1989; **141**: 359–61
 - 16 Snodgrass W. Tubularized, incised plate urethroplasty for distal hypospadias. *J Urol* 1994; **151**: 464–5
 - 17 Snodgrass W, Nguyen MT. Current technique of tubularized incised plate hypospadias repair. *Urology* 2002; **60**: 157–62
 - 18 Hollowell JG, Keating MA, Snyder HM, Duckett JW *et al*. Preservation of the urethral plate in hypospadias repair: extended applications and further experience with the onlay island flap urethroplasty. *J Urol* 1990; **143**: 98–101
 - 19 Duckett JW. The island flap technique for hypospadias repair. *Urol Clin North Am* 1980; **8**: 503–11
 - 20 Bracka A. Hypospadias repair: the two-stage alternative. *Br J Urol* 1995; **76** (Suppl. 3): 31–41
 - 21 Pope JC, Kropp BP, McLaughlin KP *et al*. Penile orthoplasty using dermal grafts in the outpatient setting. *Urology* 1996; **48**: 124–7
 - 22 Perlmutter AD, Montgomery BT, Steinhardt GF. Tunica vaginalis free graft for the correction of chordee. *J Urol* 1985; **134**: 311–4
 - 23 Bracka A. Sexuality after hypospadias repair. *BJU Int* 1999; **83** (Suppl. 3): 29–33
 - 24 Mureau MA, Slijper FM, Nijman RJ, van der Meulen JC, Verhulst FC, Slob AK. Psychosexual adjustment of children and adolescents after different types of hypospadias surgery: a norm-related study. *J Urol* 1995; **154**: 1902–8
 - 25 Bracka A. A long-term view of hypospadias. *Br J Plast Surg* 1989; **42**: 251–5
 - 26 Hayes MC, Malone PS. The use of a dorsal buccal mucosal graft with urethral plate incision (Snodgrass) for hypospadias salvage. *BJU Int* 1999; **83**: 508–9
 - 27 Barbagli G, Palminteri E, Lazzeri M, Bracka A. Penile and bulbar urethroplasty using dorsal onlay techniques. *Atlas Urol Clin* 2003; **11**: 29–41
 - 28 Barbagli G, Palminteri E, Lazzeri M, Guazzoni G. Anterior urethral strictures. *BJU Int* 2003; **92**: 497–505
 - 29 Barbagli G, Palminteri E, Bracka A, Caparros Sariol J. Penile urethral reconstruction: concepts and concerns. *Arch Esp Urol* 2003; **56**: 594–6
 - 30 Depasquale I, Park AJ, Bracka A. The treatment of balanitis xerotica obliterans. *BJU Int* 2000; **86**: 459–4

Correspondence: Gianantonio Manzoni, Department of Urology and Section of Paediatric Urology, Ospedale di Circolo, Varese, Italy.
e-mail: gianantonio Manzoni@virgilio.it

Abbreviations: TIP, tubularized incised-plate; BXO, balanitis xerotica obliterans.